



PATIENT

Bilorus Nordom

PRESENTING CLINICAL SIGNS

History: Breed sreening exam.

SPECIES

Canine

BREED

Boxer

SEX

Female

AGE

2 years

WEIGHT

59.1lbs

INTERPRETED BY

Maggie Machen Lamy,
DVM, DACVIM
(Cardiology)

IMAGING PERFORMED BY

Paul Kim, DVM

HOSPITAL NAME

Ridgefield Park
Animal Hospital

REFERRING VET

Dr. Kim

INVOICE

20499

DATE

8/11/21

ECHOCARDIOGRAM FINDINGS *limited images included.

2D, m-mode, color flow and doppler imaging is available. Normal mitral valve leaflets with no obvious prolapse into the left atrial lumen. No obvious mitral regurgitation seen. Normal left atrial dimension. Normal LV diameter with adequate myocardial function. The tricuspid valve appears subjectively normal. Normal right atrial and ventricular diameter and morphology indicating no overt evidence of pulmonary arterial hypertension. The pulmonic and aortic valves are normal in morphology and mobility. No evidence of SAS or other congenital stenosis. Normal LVOT velocities. No obvious cardiac shunts. Normal pulmonic outflow velocities; laminar flow. No pericardial or pleural effusion noted. No cardiac tumors identified.

CARDIAC CHART

CANINE CARDIAC PARAMETERS	MR VMAX (m/s)	TR VMAX (m/s)	LA/AO (Boon method)	LA/AO (Heart Base; Swe)	FS (%)	EF (%)	EPSS (cm)
NORMAL PARAMETER	4.5-5.5	<2.7	1.3	<1.6	28-40	40-100	<0.6
PATIENT	NA	NA	NM	1.3	37	70	NM
CANINE CARDIAC PARAMETERS	HR (BPM)	AV VMAX (m/s)	PV MAX (m/s)	BODY WEIGHT (kg)	LA (2D short axis Base view) (cm)	LVIDd (Avg; 2D and m-mode short axis) (cm)	LVIDs (Avg; 2D and m-mode short axis) (cm)
NORMAL PARAMETER	50-100	0.7-1.7	0.7-1.6	BELOW	BELOW	BELOW	BELOW
PATIENT	nm	1.58	0.63	26.8	3.0	4.3	2.7
*Normal chamber parameters expressed as a mean value (SD)				3	1.27 (5.3)	2.46 (2.46)	1.36 (5.5)
BODY WEIGHT DEPENDENT PARAMETERS				5	1.40 (4.5)	2.74 (5.2)	1.60 (4.7)
<i>*Note: All measurements based upon multi-modal images and methods. An average value is reported.</i>				10	1.50 (3.8)	3.27 (3.5)	2.06 (3.1)
				15	1.83 (2.0)	3.71 (2.4)	2.43 (2.1)
				20	2.02 (1.9)	4.14 (2.2)	2.80 (2.0)
				25	2.18 (2.4)	4.48 (2.9)	3.10 (2.5)
				30	2.33 (3.3)	4.83 (3.9)	3.39 (3.4)
				35	2.48 (4.3)	5.17 (5.0)	3.69 (4.5)
				40	2.62 (5.2)	5.48 (6.1)	3.96 (5.4)
				50	2.88 (7.1)	6.07 (8.3)	4.46 (7.4)

INTERPRETATION OF THE FINDINGS & FURTHER RECOMMENDATIONS

Overtly normal cardiac structure and function. No evidence of congenital issues or cardiac enlargement/dysfunction at this time.

While no abnormalities are noted on today's exam, it should also be noted that a normal congenital exam does not rule out risk to develop ARVC or DCM as this dog ages, and annual screening via echocardiography and holter monitor is recommended. A genetic test is available through NC State and may also be reasonable to screen for the risk of development of ARVC.



PATIENT

Bilorus Nordom

No contraindication for breeding at this time. **Consider an OFA evaluation as the gold standard. Additionally, a baseline ECG and holter monitor are recommended.**

SPECIES

Canine

No medications are indicated; however, omega fatty acid supplementation may be of some long-term benefit in dogs predisposed to arrhythmias. Monitor for development of a heart murmur, cough, labored breathing, exercise intolerance or collapse episodes.

BREED

Boxer

Recommend continued annual monitoring through echocardiography, holter/ECG, and/or NT-ProBNP screening, sooner if any development of clinical signs.

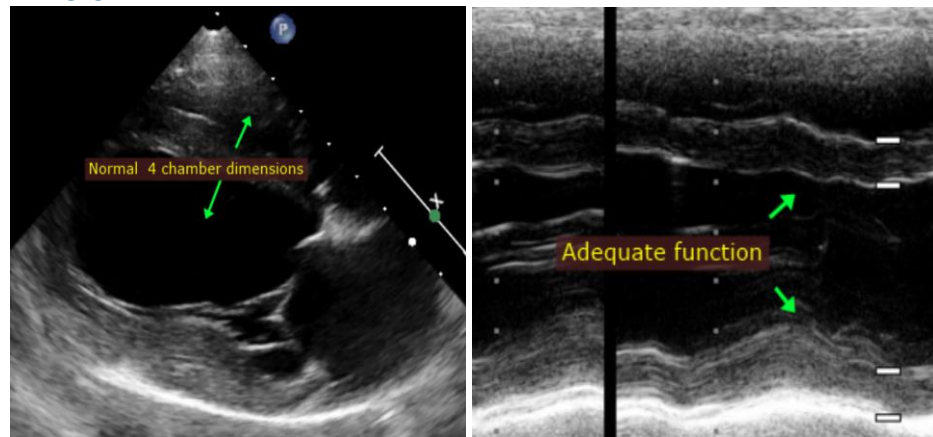
SEX

Female

IMAGES

AGE

2 years



WEIGHT

59.1lbs

The information and recommendations provided are based on the images presented by the referring veterinarian. No evaluation can be communicated regarding pathology that was not visible in the image/video clips provided.

INTERPRETED BY

Maggie Machen Lamy,
DVM, DACVIM
(Cardiology)

Thank you for this referral. This report was generated using transcription software, and minor dictation errors may be present. If the clinical or image interpretation does not parallel your findings or if I can be of any further assistance, please contact me.

IMAGING PERFORMED BY

Paul Kim, DVM

HOSPITAL NAME

Ridgefield Park
Animal Hospital

Maggie Machen Lamy, DVM
Diplomate of the American College of Veterinary Internal Medicine (Cardiology)
info@sonopath.com

REFERRING VET

Dr. Kim

INVOICE

20499

DATE

8/11/21